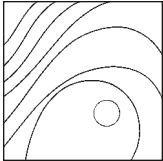


Histologic and Histomorphometric Analysis at 26 Months of a Bovine Hydroxyapatite Maxillary Sinus Graft: A Case Report



Hadi Antoun, DDS¹
Joseph Eid, DDS²
Ons Zouiten, DDS³

A variety of biomaterials are used when performing sinus augmentation techniques. Bovine hydroxyapatite (BH) has already been demonstrated to present osteoconductive properties. The aim of this article is to provide a histologic and histomorphometric analysis, at 26 months, of a bone specimen extracted from a BH maxillary sinus graft. Histomorphometric results showed 64.4% bone density and 24.4% biomaterial density. Histologic analysis revealed marked bone formation and high osteoconductive properties in the BH particles, with no associated signs of inflammation. Resorption appeared minimal. BH seems to present high biocompatibility and osteoconductive properties. Int J Periodontics Restorative Dent 2017 (7 pages). doi: 10.11607/prd.2727

When performing posterior edentulous maxillary rehabilitation, the most prevalent difficulty stems from inadequate bone volume resulting from pneumatization of the maxillary sinus and alveolar bone resorption. Enhancement of the maxillary sinus floor, first described by Boyne and James in 1980,¹ enables placement and stabilization of dental implants once bone volume is rendered adequate. A number of authors have already arrived at the conclusion that this bone augmentation method appears valid and effective.^{2,3}

Numerous bone substitutes have been used in sinus augmentation procedures.⁴⁻⁶ While autogenous bone⁷⁻⁹ coupled with histomorphometric analysis remains the benchmark for comparing respective success or clinical survival rates, these criteria presents some drawbacks, including donor site morbidity risk and frequent need for extrabuccal extraction, requiring general anesthesia and hospitalization. Furthermore, this procedure is rarely psychologically well received by patients. A number of bone substitute materials, such as allogenic^{10,11} or alloplastic¹⁰⁻¹³ graft and xenogenous graft,^{10,14,15} have therefore been tested. The ideal material should be biocompatible and gradually replaced by newly formed bone, with osteoconductive and -inductive¹⁶ properties.

¹Private Practice, Paris, France.

²Private Practice, Neuilly sur Seine, France.

³Private Practice, Orleans, France.

Correspondence to: Dr Ons Zouiten, 10 rue des Maltôtiers, 45000, Orleans, France.
Fax: +33 238 622 138. Email: dr.ons.zouiten@gmail.com

©2017 by Quintessence Publishing Co Inc.

Bovine hydroxyapatite is used as a substitute for autogenous bone in maxillary sinus graft.¹⁷ This bone, of bovine origin, is deproteinized and divested of all organic constituents and closely matches human bone tissue. An absence to date of any reports of immune reaction points to this material being perfectly biocompatible. It also demonstrates osteoconductive properties^{6,18} with no attendant inflammatory response.^{19–21} Study results pertaining to degradation vary, ranging from no resorption¹⁵ to extremely slow resorption^{6,16} or—a much rarer occurrence—resorption followed by rapid replacement with newly formed bone.¹⁹

Despite encouraging and successful results, long-term histologic studies examining the use of bovine hydroxyapatite (BH) for sinus augmentation procedures in human subjects are rare—although present—in the literature.^{17,22–24} This article is intended to provide a histologic and histomorphometric case analysis, at 26 months, of a maxillary sinus graft performed using BH.

Materials and Methods

A 49-year-old woman presented with left unilateral posterior maxillary edentulousness in the molar area (Fig 1) and underwent lateral maxillary sinus augmentation in February 2006. Clinical and radiologic examinations revealed 2 to 4 mm of residual subsinus bone height, which required preimplant bone augmentation. A computed tomography scan confirmed mid-meatus permeability, no sinus pa-

thology, and a healthy-looking sinus membrane of normal thickness. No clear indication of a pronounced bony septum was seen. Based on the Misch classification, this sinus would be ranked SA4.²⁵ The patient was a nonsmoker and did not present any specific health-related problems.

Surgical Procedure

Following administration of local anesthesia, an incision was made on the edentulous crest along with a complementary anterior vertical incision. A full-thickness mucoperiosteal flap was elevated, and the alveolar ridge and the maxillary external wall were exposed. Lateral access was enabled by performing an osteotomy using a round burr and thoroughly irrigating the area with a sterile saline solution. The sinus membrane was carefully lifted upward using foam-tipped instruments with varied curves until it was fully detached from the anterior, posterior, and medial walls. No tears in the sinus mucosa were observed during the procedure (Fig 2). The bone window was detached and later crushed and affixed to the maxillary sinus anteroinferior wall. The bone substitute material (2 g 0.25 to 1-mm particle size Bio-Oss, Geistlich) was mixed with physiologic saline and then gently compacted in the resultant sinus cavity to its medial wall. A resorbable membrane (Bio-Gide, Geistlich) was used to cover the window to prevent connective tissue ingrowth in the graft area. The flap was then repositioned and sutured.

Suture removal was performed 2 weeks postsurgery. During the pre- and postoperative phases, benzodiazepam (20 mg 1 hour prior), amoxicillin/clavulanic acid (2 g 1 hour prior, followed by 2 g daily for 7 days), prednisone (80 mg 1 hour prior, 60 mg the next day, and 40 mg on the second day postsurgery), and chlorhexidine 0.2% mouthrinse (3 times daily for 2 weeks) were administered to the patient.

Implant placement had been scheduled for 6 months postsurgery. For personal reasons, however, the patient was unavailable for this procedure until 26 months had elapsed. Cone beam computed tomography was used to verify maxillary sinus permeability and radiologic integration of the graft material.

Two 5 × 13-mm nonsubmerged implants (Replace Select Tapered, Nobel Biocare) were placed at the sites of the maxillary left first and second molars, and final abutments (0.5 mm Snappy WP, Nobel Biocare) were connected and tightened to 35 Ncm (Fig 3).

In the case under discussion, a bone core was extracted, once patient approval had been secured, using a 3-mm (outer diameter) trephine (Fig 4). The resultant bone biopsy specimen was maintained intact in the trephine to prevent bone tissue scattering without subsequent changes in dimensions.

The specimen was fixed in 4% buffered formalin and subsequently dehydrated and embedded in polymethylmetacrylate resin without prior decalcification (Laboratoire Biomatech). A longitudinal slice, created using application-specific

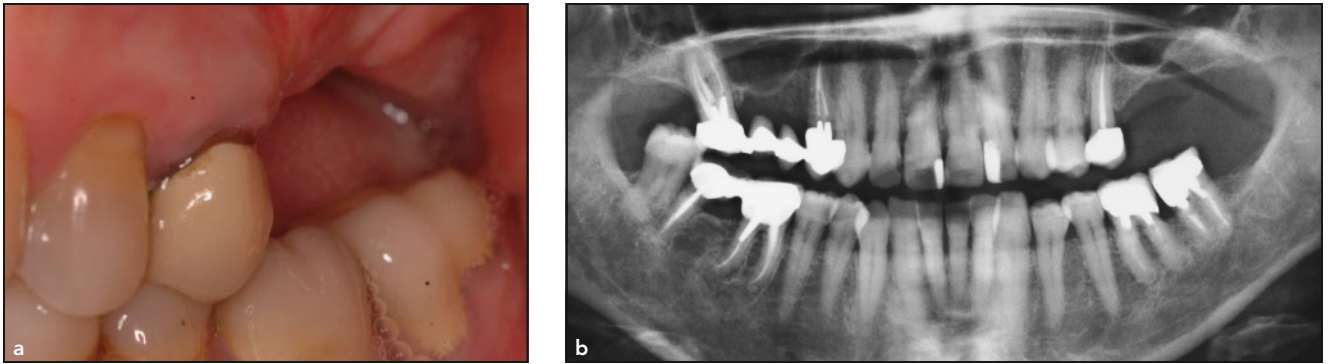


Fig 1 Preoperative clinical and radiologic examination. (a) Clinical examination showing the absence of the maxillary left first and second molars. (b) Radiologic examination revealed a prominent sinus. Dental implants could not be stabilized without bone augmentation prior to implant placement. (c) 3D radiologic examination, highlighting mid-meatus permeability. The sinus membrane was of normal thickness and had a healthy appearance, and residual bone height was between 2 and 4 mm.

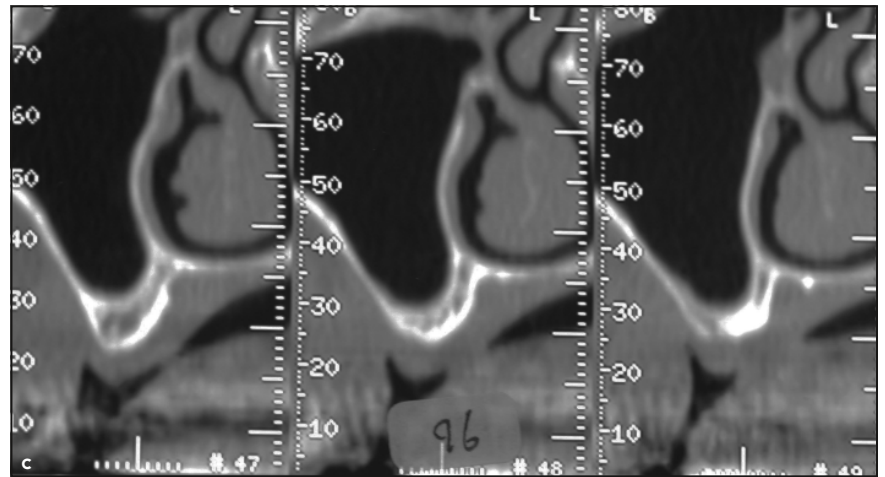
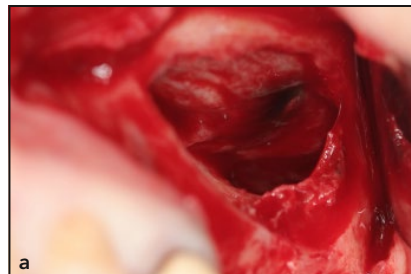


Fig 2 Perioperative clinical view. (a) A lateral access window was created via osteotomy. Sinus mucosa was carefully lifted upward. No tears were observed. (b) Biomaterial (BioOss, Geistlich) was gently compacted into the space thus created. The access window was then covered with a resorbable membrane (BioGide, Geistlich).



equipment (EXACT Micro Cutting System), was then ground and polished, deploying the technique described by Donath and Breuner.²⁶ A Paragon stain was then applied to the bone segment to facilitate qualitative, semiquantitative, and quantitative histologic analysis.

The slice underwent qualitative examination under a Nikon Eclipse

E600 microscope equipped with $\times 2$, $\times 4$, $\times 10$, $\times 20$, and $\times 40$ lenses, connected to a Nikon DN 100 digital camera. The histomorphometric analysis was conducted using a microscope (AXIOSKOP, Zeiss) equipped with $\times 5$, $\times 10$, $\times 20$, and $\times 40$ lenses, as well as a Samba image analysis system (Samba Technologies).

The following parameters were quantified:

- Density of graft material, bone tissue, fibrous connective tissue, and bone lacunae
- Percentages of contact between graft material and, respectively, surrounding bone, fibrous tissue, and bone lacunae

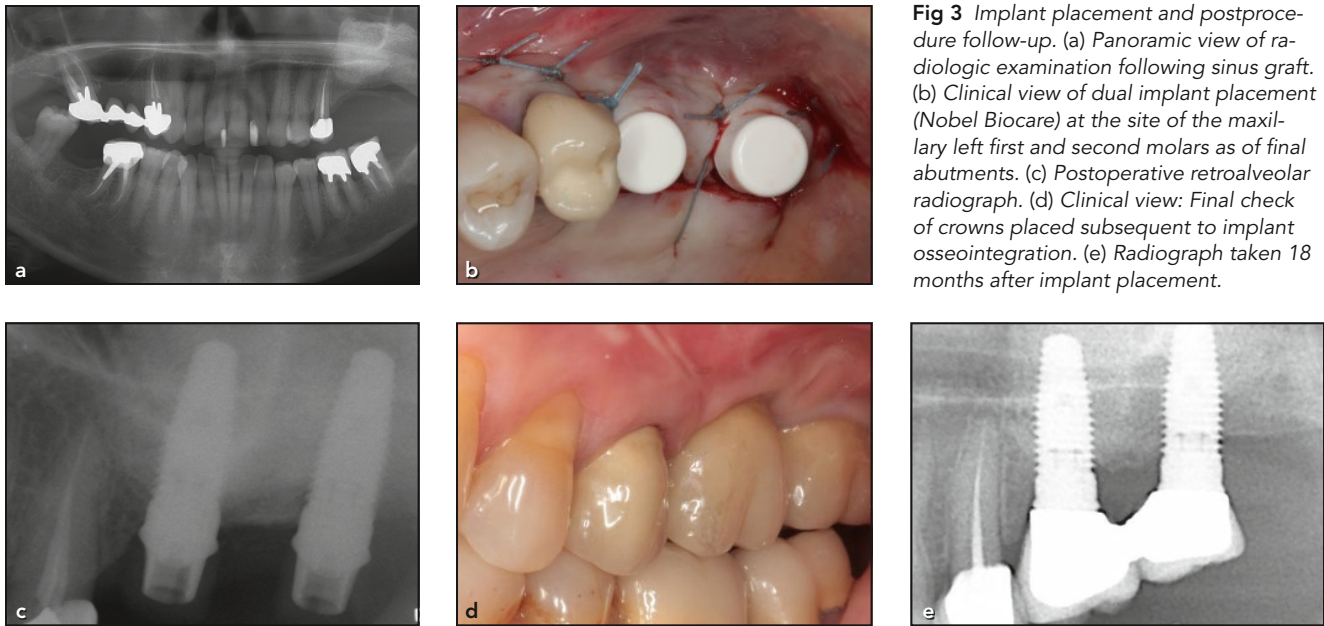


Fig 3 Implant placement and postprocedure follow-up. (a) Panoramic view of radiologic examination following sinus graft. (b) Clinical view of dual implant placement (Nobel Biocare) at the site of the maxillary left first and second molars as of final abutments. (c) Postoperative retroalveolar radiograph. (d) Clinical view: Final check of crowns placed subsequent to implant osseointegration. (e) Radiograph taken 18 months after implant placement.

Fig 4 Bone core extracted using 3-mm (outer diameter) trephine in grafted maxillary sinus. (a) This bone biopsy specimen was kept intact in the trephine to minimize bone tissue scattering as much as possible and avoid any resultant changes in dimensions. (b) 3D radiologic examination demonstrating a well-integrated graft as well as the implant.

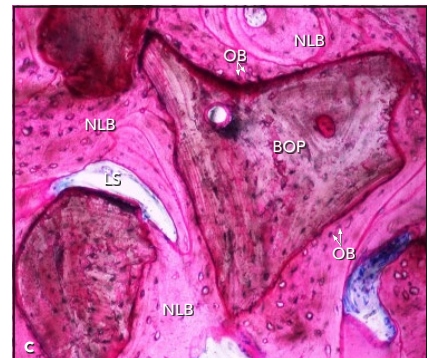
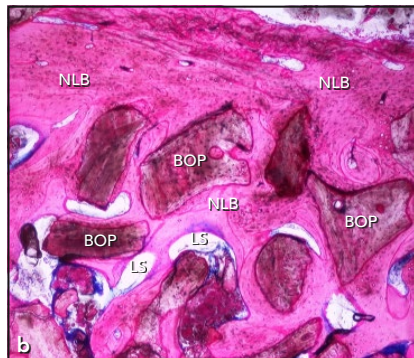
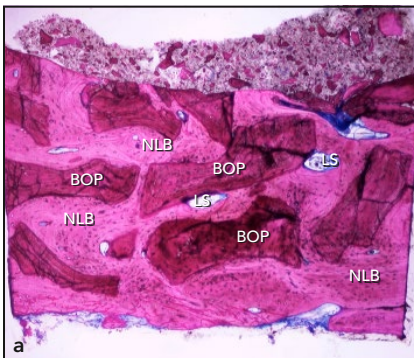
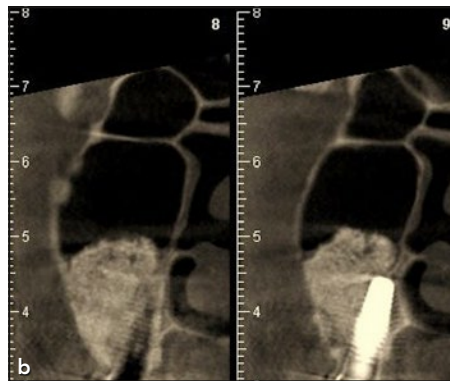
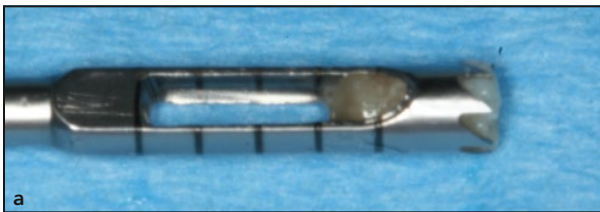


Fig 5 Histologic slices of biopsy specimen taken 26 months post-sinus graft (slice was ground, polished, and fixed in Paragon). (a) Longitudinal view of the entire core showing BioOss particles (BOP), new lamellar bone (NLB), and small lacunar spaces (LS). (b) Longitudinal slice (created using trephine). Enlarged $\times 4$. Majority of Bio-Oss particles (BOP) are surrounded by newly formed concentric lamellar bone (NLB). Presence of lacunae (LS) was minimal. No immune reaction was observed. (c) Enlarged $\times 10$. Osteoblasts (OB) deposited newly formed bone directly onto the biomaterial surface. No lacunar spaces (LS) were observed in the bone/biomaterial interface.

Results

The semiquantitative histologic analysis shows low degradation of the material but excellent osseointegration, a good amount of new bone with good bone remodeling, and osseointegration. Very few lymphocytes and vessels were observed. This analysis did not show polymorphonuclear cells, plasma cells, macrophages, giant cells, osteoclasts, or fibrocytes. No fibrin or fibronectin was found and no necrosis or degeneration was observed.

The analysis of the histomorphometric parameters demonstrated that the presence of newly formed bone was highly evident. Also observed was strong evidence of 64.4% bone tissue growth, achieved by osteoconduction through bone substitute granules. The newly formed bone was in direct contact with the Bio-Oss particles, which in turn had fully integrated with the bone tissue, achieving 88.3% bone-to-particle contact. Bone formation was advanced (Fig 5). No biologically significant level of immune reaction was noted, and the presence of osteoblasts and a vascular system was also observed.

Fibrous connective tissue and lacunae density (2.3% and 8.9%, respectively) appeared quite low, which demonstrates highly limited contact in the biomaterial interface (5.2% and 6.5%, respectively). No osteoclasts or resorption lacunae were apparent. Granule resorption appeared to be minimal: graft material density was 24.4%.

Discussion

A histologic analysis involving human subjects (20 patients) who underwent sinus augmentation using Bio-Oss was conducted by Piatelli et al¹⁷ over a period of 6 months to 4 years. The authors noted that most of the biomaterial particles are surrounded by compact, mature bone. Contact between small newly formed bone and blood vessels, mesenchymal cells, and osteoblasts were observed. Analysis of specimens after 18 months also revealed the presence of osteoclasts involved in the slow resorption of bone substitute particles.

Histomorphometric assessments have been conducted by a number of authors examining the proportion of newly formed bone following a BH sinus graft. The average rate of newly formed bone observed by Yildirim et al²⁷ was 14.7% at 6 months, while Valentini et al²⁸ reported a 27.5% rate at 12 months and Artzi et al²⁹ a 42.1% average rate for the same period. Lee et al²³ compared healing at 6 and 12 months, using the same specimens, and noted a significantly higher average rate of new bone formation at 12 months (26.6%) than at 6 months (18.3%). Similarly, the average percentage of bone-to-particle contact was significantly higher at 12 months (42.2%) than at 6 months (31.8%). In a more recent study, Lee et al³⁰ found that the average for regenerated bone was 19% at 9 months.

In the present clinical case, the density of newly formed bone 26 months following sinus augmentation was 64.4%. Compared to

the above-cited studies, this bone density appears to increase significantly with the passage of time. The histomorphometric assessment conducted by Traini et al²⁴ 9 years post-BH maxillary sinus graft resulted in a finding of 46% \pm 4.67% newly formed bone. These results were lower than in the present study. The authors note a positive correlation in this regard over time, since the increase in new bone formation was even more pronounced after 9 years compared to the results obtained by Qiu et al³¹ at 3 to 8 months and by Scarano et al³² at 1 to 4 years. The present results are comparable to those achieved by Sartori et al²² at 2 years, demonstrating that new bone formation essentially appears to increase during the first two years, followed by a slowdown in subsequent years. This should be confirmed via larger samplings and specimens extracted from the same patients, which would present ethical problems. A comparison of histomorphometric data was performed by Sartori et al²² at 8 months, 2 years, and 10 years postsurgery. At 8 months postprocedure, the average quantity of bone tissue observed (including medullar spaces) in 20 distinct thin slices was 29.8% \pm 2.6%. Bone tissue had increased to 69.7% \pm 2.7% at the 2-year mark, and to 86.7% \pm 2.8% after 10 years. A comparison of averages at each interval pointed to a highly significant trend toward increased bone formation related to gradual resorption of Bio-Oss. All three specimens (8 months, 2 years, and 10 years) revealed Bio-Oss particles fully surrounded by newly formed lamellar

bone and presenting slow resorption. Ohayon³³ compared the histomorphometric results at 6 months and 5 years postsurgery on the same human clinical case and found 21.1% and 44 % of newly formed bone, respectively.

In the literature, Bio-Oss particle resorption is a controversial topic. McAllister et al³⁴ observed a 62% increase in new bone formation in animals at 7.5 months, rising to 70% at 18 months, while the percentage of bone substitute particles decreased from 19% to 6% during the same period, prompting their suggestion of BH particle resorption and replacement by newly formed bone. Wallace et al³⁵ observed a complete disappearance of inorganic bovine bone at the 20-month mark. Conversely, Lee et al²³ did not report any osteoclastic activity in human specimens after 12 months, nor did they observe any significant difference in BH particle rates between specimens at 6 and 12 months. Similarly, Yildirim et al^{27,36} observe no resorption and suggest a slow rate of BH particle resorption, comparable to that of physiologic bone remodeling. Traini et al²⁴ perceive BH as a biomaterial that demonstrates a very slow resorption rate and tentatively attribute this finding to inhibition of osteoclastic activity in the BH particle microenvironment, attributable to a high concentration of Ca²⁺ ions in this area. Finally, Valentini et al¹⁵ note that the absence of BH particle resorption does not interfere with implant osseointegration, since the implant surface does not come in contact with the bone substitute particles, which therefore

remain at a distance. In the subject case of this report, the intrinsic bone growth (64.4%) and reduced material density (24.4%) point to slow bone substitute particle resorption despite the observed lack of osteoclastic activity.

This slow resorption is interesting from a clinical and a radiologic standpoint, since it enables graft stability over time while suppressing sinus pneumatization. These two conditions were essential to ensuring the feasibility of treatment for this patient and for implant placement 26 months postgraft.

Conclusions

Histologic and histomorphometric results obtained in the present case reveal significant new bone formation, which supports the use of BH particles as a bone substitute in maxillary sinus bone augmentation. The tissue analyzed in this study is composed of graft particles that are closely related to the newly formed bone. Biomaterial residual particles appear to be surrounded and connected by bone tissue. Notwithstanding the limitations of this clinical case study, it can be deduced that the volume of newly formed bone grows with time. The elevated osteoconductive properties observed in the BH particles do not interfere with the usual bone healing process and appear to promote new bone formation. Resorption of these elements appears minimal over 26 months of healing, which enabled the conservation of increased bone volume and treat-

ment of this patient in optimal conditions despite the significant lapse in time between sinus filling and implant placement. These results will need to be confirmed through prospective and retrospective studies.

Acknowledgments

The authors reported no conflicts of interest related to this study.

References

1. Boyne PJ, James RA. Grafting of the maxillary sinus floor with autogenous marrow and bone. *J Oral Surg* 1980;38: 613–616.
2. Lundgren S, Moy P, Johansson C, Nilsson H. Augmentation of the maxillary sinus floor with particulated mandible: A histologic and histomorphometric study. *Int J Oral Maxillofac Implants* 1996;11: 760–766.
3. Haas R, Mailath G, Dörtbudak O, Watzek G. Bovine hydroxyapatite for maxillary sinus augmentation: Analysis of interfacial bond strength of dental implants using pull-out tests. *Clin Oral Implants Res* 1998;9:117–122.
4. Hürzeler MB, Quiñones CR, Kirsch A, et al. Maxillary sinus augmentation using different grafting materials and dental implants in monkeys. Part I. Evaluation of anorganic bovine-derived bone matrix. *Clin Oral Implants Res* 1997;8:476–486.
5. Wetzel AC, Stich H, Caffesse RG. Bone apposition onto oral implants in the sinus area filled with different grafting materials. A histological study in beagle dogs. *Clin Oral Implants Res* 1995;6:155–163.
6. Berglundh T, Lindhe J. Healing around implants placed in bone defects treated with Bio-Oss. An experimental study in the dog. *Clin Oral Implants Res* 1997;8: 117–124.
7. Kent JN, Block MS. Simultaneous maxillary sinus floor bone grafting and placement of hydroxylapatite-coated implants. *J Oral Maxillofac Surg* 1989;47: 238–242.

8. Jensen J, Simonsen EK, Sindet-Pedersen S. Reconstruction of the severely resorbed maxilla with bone grafting and osseointegrated implants: A preliminary report. *J Oral Maxillofac Surg* 1990;48:27–32.
9. Raghoobar GM, Brouwer TJ, Reintsema H, Van Oort RP. Augmentation of the maxillary sinus floor with autogenous bone for the placement of endosseous implants: A preliminary report. *J Oral Maxillofac Surg* 1993;51:1198–1203.
10. Smiler DG, Johnson PW, Lozada JL, et al. Sinus lift grafts and endosseous implants. Treatment of the atrophic posterior maxilla. *Dent Clin North Am* 1992;36:151–186.
11. Small SA, Zinner ID, Panno FV, Shapiro HJ, Stein JL. Augmenting the maxillary sinus for implants: Report of 27 patients. *Int J Oral Maxillofac Implants* 1993;8:523–528.
12. Tidwell JK, Blijdorp PA, Stoeltinga PJ, Brouns JB, Hinderks F. Composite grafting of the maxillary sinus for placement of endosteal implants. A preliminary report of 48 patients. *Int J Oral Maxillofac Surg* 1992;21:204–209.
13. Moy PK, Lundgren S, Holmes RE. Maxillary sinus augmentation: Histomorphometric analysis of graft materials for maxillary sinus floor augmentation. *J Oral Maxillofac Surg* 1993;51:857–862.
14. Avera SP, Stampley WA, McAllister BS. Histologic and clinical observations of resorbable and nonresorbable barrier membranes used in maxillary sinus graft containment. *Int J Oral Maxillofac Implants* 1997;12:88–94.
15. Valentini P, Abensur D, Densari D, Graziani JN, Hämmerle C. Histological evaluation of Bio-Oss in a 2-stage sinus floor elevation and implantation procedure. A human case report. *Clin Oral Implants Res* 1998;9:59–64.
16. Jensen SS, Aaboe M, Pinholt EM, Hjørting-Hansen E, Melsen F, Ruyter IE. Tissue reaction and material characteristics of four bone substitutes. *Int J Oral Maxillofac Implants* 1996;11:55–66.
17. Piattelli M, Favero GA, Scarano A, Orsini G, Piattelli A. Bone reactions to anorganic bovine bone (Bio-Oss) used in sinus augmentation procedures: A histologic long-term report of 20 cases in humans. *Int J Oral Maxillofac Implants* 1999;14:835–840.
18. Pinholt EM, Bang G, Haanaes HR. Alveolar ridge augmentation in rats by Bio-Oss. *Scand J Dent Res* 1991;99:154–161.
19. Wheeler SL, Holmes RE, Calhoun CJ. Six-year clinical and histologic study of sinus-lift grafts. *Int J Oral Maxillofac Implants* 1996;11:26–34.
20. Valentini P, Abensur D, Wenz B, Peetz M, Schenk R. Sinus grafting with porous bone mineral (Bio-Oss) for implant placement: A 5-year study on 15 patients. *Int J Periodontics Restorative Dent* 2000;20:245–253.
21. Clergeau LP, Danan M, Clergeau-Guérithault S, Brion M. Healing response to anorganic bone implantation in periodontal intrabony defects in dogs. Part I. Bone regeneration. A microradiographic study. *J Periodontol* 1996;67:140–149.
22. Sartori S, Silvestri M, Forni F, Icaro Cornaglia A, Tesi P, Cattaneo V. Ten-year follow-up in a maxillary sinus augmentation using anorganic bovine bone (Bio-Oss). A case report with histomorphometric evaluation. *Clin Oral Implants Res* 2003;14:369–372.
23. Lee YM, Shin SY, Kim JY, Kye SB, Ku Y, Rhyu IC. Bone reaction to bovine hydroxyapatite for maxillary sinus floor augmentation: Histologic results in humans. *Int J Periodontics Restorative Dent* 2006;26:471–481.
24. Traini T, Valentini P, Iezzi G, Piattelli A. A histologic and histomorphometric evaluation of anorganic bovine bone retrieved 9 years after a sinus augmentation procedure. *J Periodontol* 2007;78:955–961.
25. Misch CE. Maxillary sinus augmentation for endosteal implants: Organized alternative treatment plans. *Int J Oral Implants* 1987;4:49–58.
26. Donath K, Breuner G. A method for the study of undecalcified bones and teeth with attached soft tissues. The Säge-Schliff (sawing and grinding) technique. *J Oral Pathol* 1982;11:318–326.
27. Yildirim M, Spiekermann H, Biesterfeld S, Edelhoff D. Maxillary sinus augmentation using xenogenic bone substitute material Bio-Oss in combination with venous blood. A histologic and histomorphometric study in humans. *Clin Oral Implants Res* 2000;11:217–229.
28. Valentini P, Abensur D, Wenz B, Peetz M, Schenk R. Sinus grafting with porous bone mineral (Bio-Oss) for implant placement: A 5-year study on 15 patients. *Int J Periodontics Restorative Dent* 2000;20:245–253.
29. Artzi Z, Nemcovsky CE, Tal H, Dayan D. Histopathological morphometric evaluation of 2 different hydroxyapatite-bone derivatives in sinus augmentation procedures: A comparative study in humans. *J Periodontol* 2001;72:911–920.
30. Lee DZ, Chen ST, Darby IB. Maxillary sinus floor elevation and grafting with deproteinized bovine bone mineral: A clinical and histomorphometric study. *Clin Oral Implants Res* 2012;23:918–924.
31. Qiu S, Rao DS, Palnitkar S, Parfitt AM. Reduced iliac cancellous osteocyte density in patients with osteoporotic vertebral fracture. *J Bone Miner Res* 2003;18:1657–1663.
32. Scarano A, Pecora G, Piattelli M, Piattelli A. Osseointegration in a sinus augmented with bovine porous bone mineral: Histological results in an implant retrieved 4 years after insertion. A case report. *J Periodontol* 2004;75:1161–1166.
33. Ohayon L. Histological and histomorphometric evaluation of anorganic bovine bone used for maxillary sinus floor augmentation: A six-month and five-year follow-up of one clinical case. *Implant Dent* 2014;23:239–244.
34. McAllister BS, Margolin MD, Cogan AG, Buck D, Hollinger JO, Lynch SE. Eighteen-month radiographic and histologic evaluation of sinus grafting with anorganic bovine bone in the chimpanzee. *Int J Oral Maxillofac Implants* 1999;14:361–368.
35. Wallace SS, Froum SJ, Tarnow DP. Histologic evaluation of a sinus elevation procedure: A clinical report. *Int J Periodontics Restorative Dent* 1996;16:46–51.
36. Yildirim M, Spiekermann H, Handt S, Edelhoff D. Maxillary sinus augmentation with the xenograft Bio-Oss and autogenous intraoral bone for qualitative improvement of the implant site: A histologic and histomorphometric clinical study in humans. *Int J Oral Maxillofac Implants* 2001;16:23–33.